

# A Pediatric Case

Pennsylvania Academy of Dermatology  
September 2023

Sofia Oluwole MD, PhD  
Dr. Katherine Marks

1

7 year old female

Feb 2023

- Diffuse rash x 2 months
- Involves the arms, legs, chest and back.
- Spares the face and genital area.
- Patient was diagnosed with Strep throat and Scarlet fever at time of rash onset
- Very pruritic
- No improvement with hydrocortisone, triamcinolone, and Atarax
- No other family members have been ill or developed a rash
- No new soaps, detergents, and lotions

2

**Medical History**

- Impetigo

**Surgical History**

- None

**Social History**

- Lives with parents and 3 siblings

**Family History**

- Mother, sister, grandmother - eczema

**Medications**

- Mupirocin
- Tacrolimus
- Clobetasol 0.05% ointment
- Hydrocortisone 2.5% cream
- Loratadine
- Hydroxyzine

**Allergies**

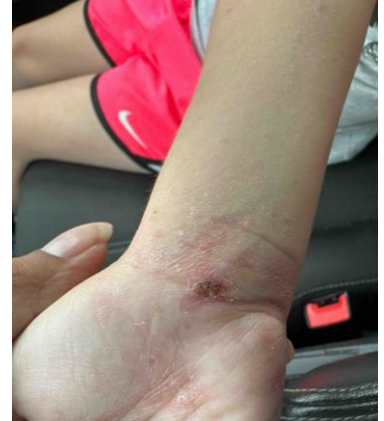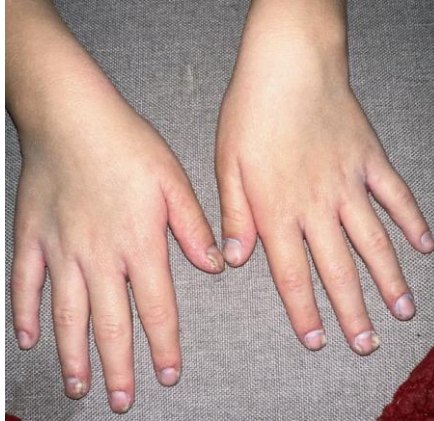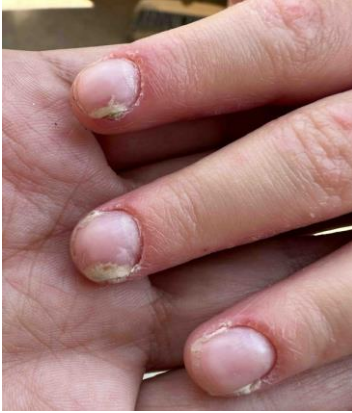- No known allergies

3

- Prescribed clobetasol and tacrolimus
- Follow- up in 1 month
- No significant improvement --> start Dupilumab

4

## Before Starting Dupilumab



5



### March 2023

Dupilumab started



### May 2023

Significant improvement after 1st dose

Improvement 2 weeks after 2nd dose but increased pruritus in 2 weeks leading up to next dose.

Pruritic dry patches on neck, occipital scalp, abdomen, chest, back

Palms and fingers with red, scaly, cracked areas of skin and multiple thickened and discolored fingernails

3rd dose is administered

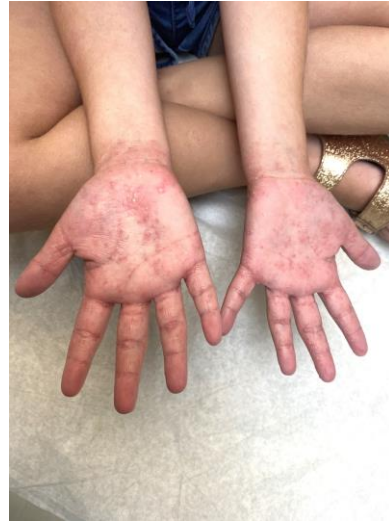

### Jul 2023

Worsening pruritus, redness, scaling days before 5th dose of dupilumab

6

## Three Months After Starting Dupixent



7

### Reassessing Diagnosis...

- Atopic dermatitis
- Allergic contact dermatitis
- Dyshidrotic eczema
- Irritant contact dermatitis
- Psoriasis
- Scabies
- Tinea infection

8

## Diagnosis

- Scabies preparation from bilateral hand scraping – identified mite eggs and mite fecal pellets

9

## Treatment

- Patient
  - PO Ivermectin and permethrin cream
  - Stopped Dupixent
- Parents
  - PO Ivermectin
- Siblings
  - Permethrin cream

10

# Norwegian Scabies in an Atopic Patient Under Dupilumab Treatment

Laura Rodriguez-Lago  and Leopoldo Borrego

## Erythrodermic scabies in an immunocompetent patient



Ronan Talty, BS,<sup>a,b</sup> Goran Micevic, MD, PhD,<sup>a,b</sup> William Damsky, MD, PhD,<sup>a,b</sup> and Brett A. King, MD, PhD<sup>b</sup>

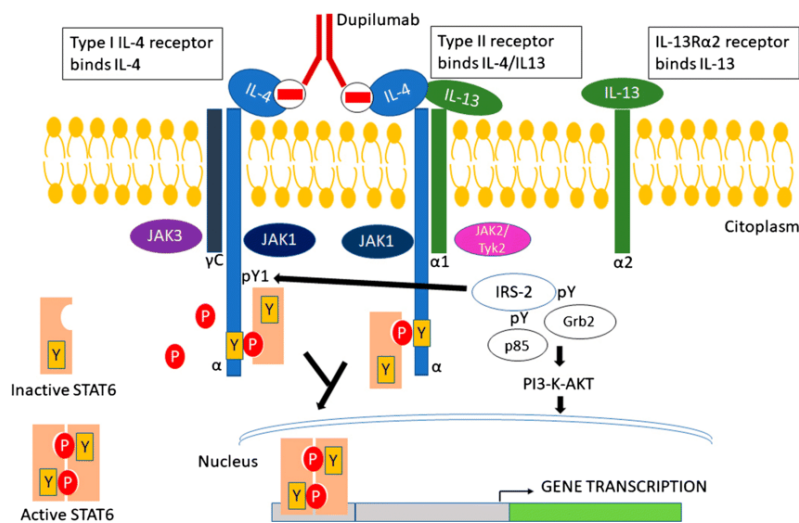
CASE REPORTS | MAY 01 2021

## Demodex Folliculitis and Recent Dupilumab Administration

Andrew C. Krakowski, MD ; Stephen C. Senft, MD; Warren R. Heymann, MD

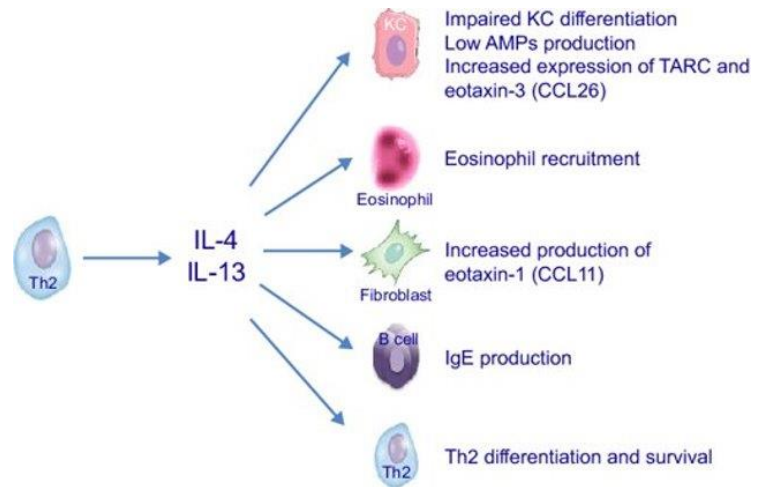
11

### Mechanism of Action



12

Dupilumab  
modulates TH2  
mediated  
inflammation, a  
key component of  
fighting parasitic  
infections



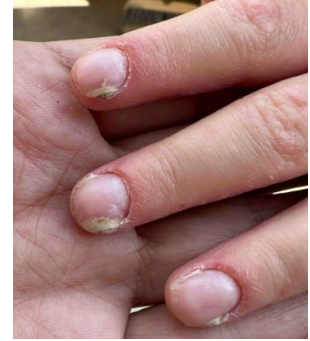
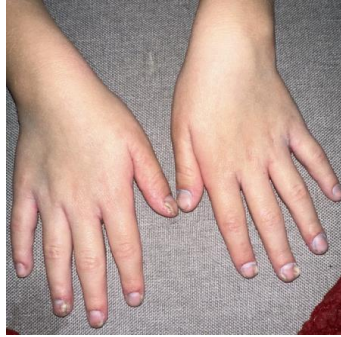13

## Reassessing Diagnosis...

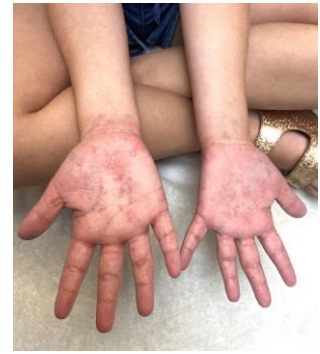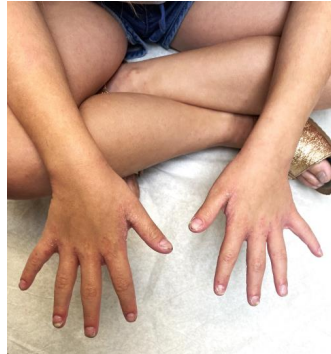- Atopic dermatitis
- Allergic contact dermatitis
- Dyshidrotic eczema
- Irritant contact dermatitis
- Psoriasis
- Scabies
- Tinea infection

14

Before Starting Dupilumab



Three Months on Dupilumab



15

### Dupilumab-induced psoriasiform dermatitis

Karlee Novice, MD, Department of Dermatology Henry Ford Health System, Detroit, MI; Jesse Veenstra, MD, PhD, Department of Dermatology Henry Ford Health System, Detroit, MI; Dana Siegel, BS,

### Psoriasiform dermatitis during dupilumab treatment for moderate-to-severe atopic dermatitis in children

Jennifer J Parker <sup>1</sup>, Jeffrey L Sugarman <sup>2</sup>, Nanette B Silverberg <sup>3</sup>, Mercedes Elena Gonzalez <sup>4</sup>, Michele L Ramien <sup>4</sup>, Joyce M C Teng <sup>5</sup>, <sup>6</sup>, Amy S Paller <sup>1</sup>

### De novo pustular psoriasis associated with dupilumab therapy in a young male with the diagnosis of atopic dermatitis

Pinar Incel Uysal <sup>1</sup>, Omer Gunhan <sup>2</sup>

### Dupilumab-associated psoriasis and psoriasiform dermatitis in patients with atopic dermatitis

Fiore Casale <sup>1</sup>, Cristina Nguyen <sup>1</sup>, Allison Dobry <sup>1</sup>, Janellen Smith <sup>1</sup>, Natasha Atanaskova Mesinkovska <sup>1</sup> •

16





**Volume 239, Issue 4**

August 2023



REVIEW ARTICLES | AUGUST 08 2023

## Dupilumab-Associated Psoriasis and Psoriasiform Manifestations: A Scoping Review

Subject Area:  Dermatology,  Immunology and Allergy.Zheng Su; Yue-Ping Zeng  

17



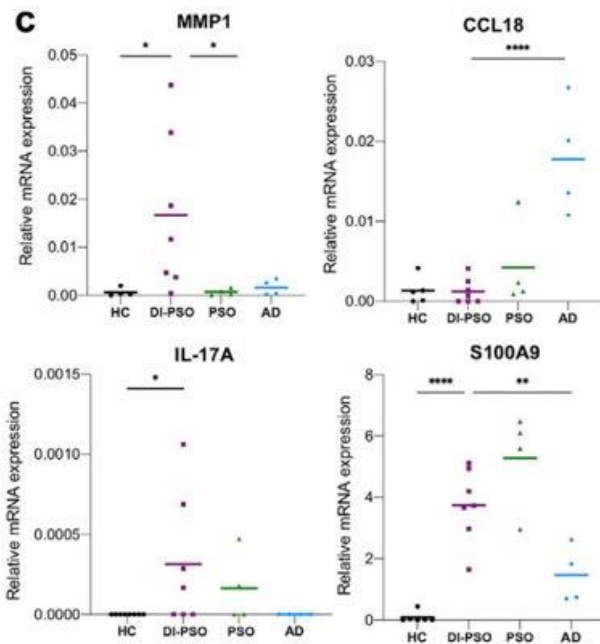
Journal of Investigative Dermatology

[> J Invest Dermatol. 2023 May;143\(5\):711-721.e7. doi: 10.1016/j.jid.2022.10.015. Epub 2023 Jan 5.](#)

## IL-4/IL-13 Inhibitors for Atopic Dermatitis Induce Psoriatic Rash Transcriptionally Close to Pustular Psoriasis

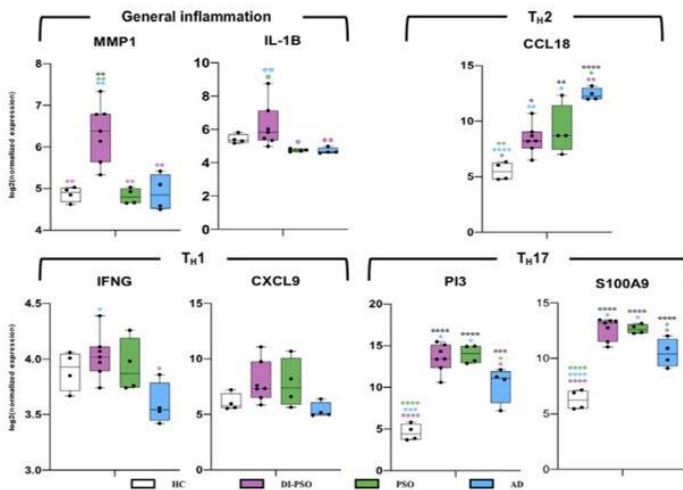
Chloé Grolleau <sup>1</sup>, Andreea Calugareanu <sup>2</sup>, Sarah Demouche <sup>1</sup>, Audrey Nosbaum <sup>3</sup>,  
 Delphine Staumont-Sallé <sup>4</sup>, Hélène Aubert <sup>5</sup>, Charles Cassius <sup>1</sup>, Marie Jachiet <sup>6</sup>, Anne Saussine <sup>6</sup>,  
 Martine Bagot <sup>6</sup>, Hervé Bachelez <sup>7</sup>, Maxime Battistella <sup>8</sup>, Claire Hotz <sup>9</sup>, Aurélie Du Thanh <sup>10</sup>,  
 Marie-Noëlle Crépy <sup>11</sup>, David Bergerat <sup>12</sup>, Marine Merandet <sup>12</sup>, Rachel Onifarasoaniaina <sup>13</sup>,  
 Antonio Alberdi <sup>14</sup>, Alexandre How-Kit <sup>15</sup>, Jean-David Bouaziz <sup>16</sup>, Hélène Le-Buanec <sup>12</sup>

18



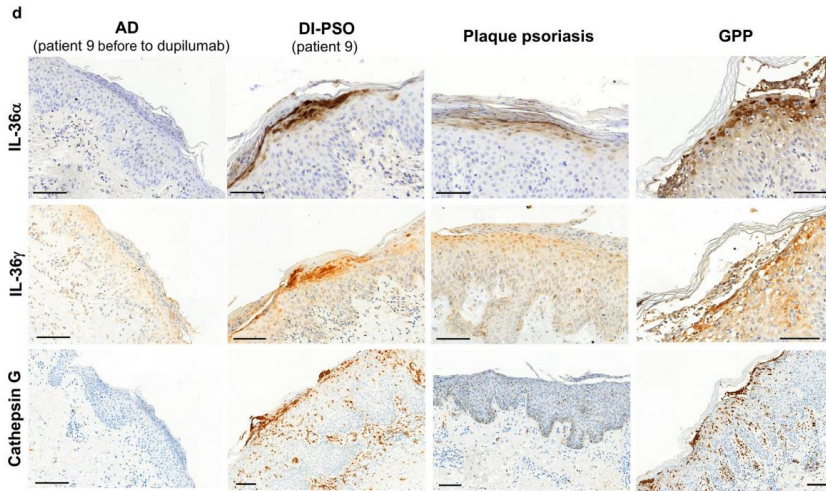
Dupilumab-induced psoriasis shows enrichment of Th17 pathway characterizing immune polarization

19



Dupilumab-induced psoriasis shows enrichment of Th17 pathway characterizing immune polarization

20



Dupilumab-induced psoriasis shows enrichment in IL-1B and IL-36a/Y URs closer to those of generalized pustular psoriasis than plaque psoriasis

21

## Next Steps

Patient scheduled for follow-up visit Sept 2023:

- Restart Dupixent?
- Recheck/re-treat for scabies?
- Treat as psoriasis?
- Biopsy?

22

## References

- Rodriguez-Lago, L, Borrego L. Norwegian Scabies in atopic patient under dupilumab treatment. *Dermatitis*. 2022;33(5).
- Talty R, Micevic G, Damsky W, King BA. Erythrodermic scabies in an immunocompetent patient. *JAAD Case Reports*. 2022;29:112-115
- Krakowski AC, Senft SC, Heymann WR. Demodex folliculitis and recent dupilumab administration. *Pediatrics*. 2021; 147(5)
- Su Z, Zeng Y. Dupilumab-associated psoriasis and psoriasiform manifestations: a scoping review. *Dermatology*. 2023; 229(4)
- Grolleau C, Calugareanu A, Demouche S. Il-4/Il-13 Inhibitors for Atopic Dermatitis Induce Psoriatic Rash Transcriptionally Close to Pustular Psoriasis. *Journal of Investigative Dermatology*. 2023; 143(5)

23

THANK YOU!

24